



IN THE NAME OF GOD



# Perinatal Asphyxia

Case presentation

Dr. S. yousofi

Shiraz University Of Medical sciences

Perinatology Department



- 35 y/o G2L1 39wks and 5days came with labor pain and ROM since 1hr before admission (1AM)
- G1: NVD
- PM Hx: not remarkable

### Vital signs

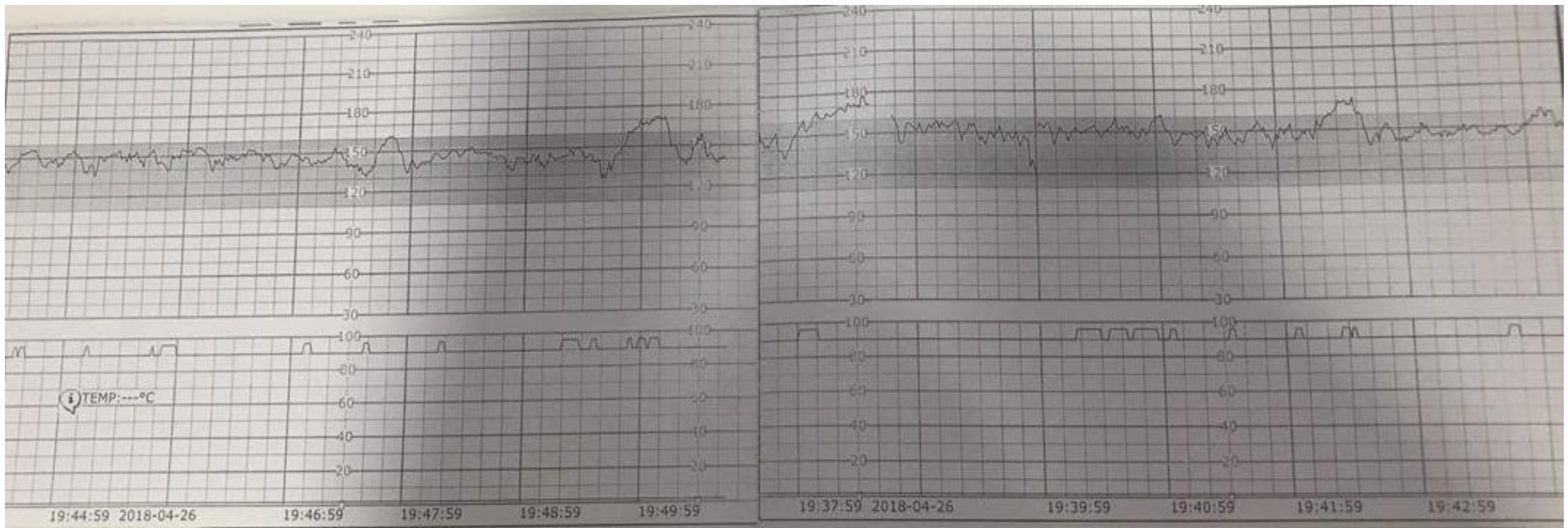
- PR: 90 RR:18 Temp: 37.3 BP: 110/70 mmHg

### Exam:

- Vx / 2f /50% /-3 / R/C (1AM)



# NST on admission

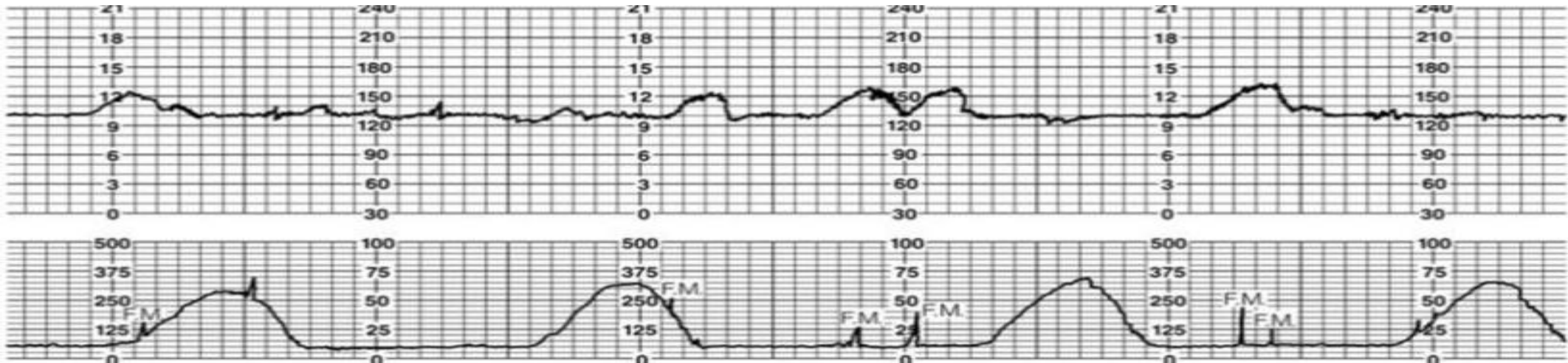




## The patient's condition after one hour

No change on exam : Vx / 2f / 50% / -3 / R/C Temp 37.3 (2AM)

- So labor Induction was started
- OCT: Negative





## The patient's condition after that

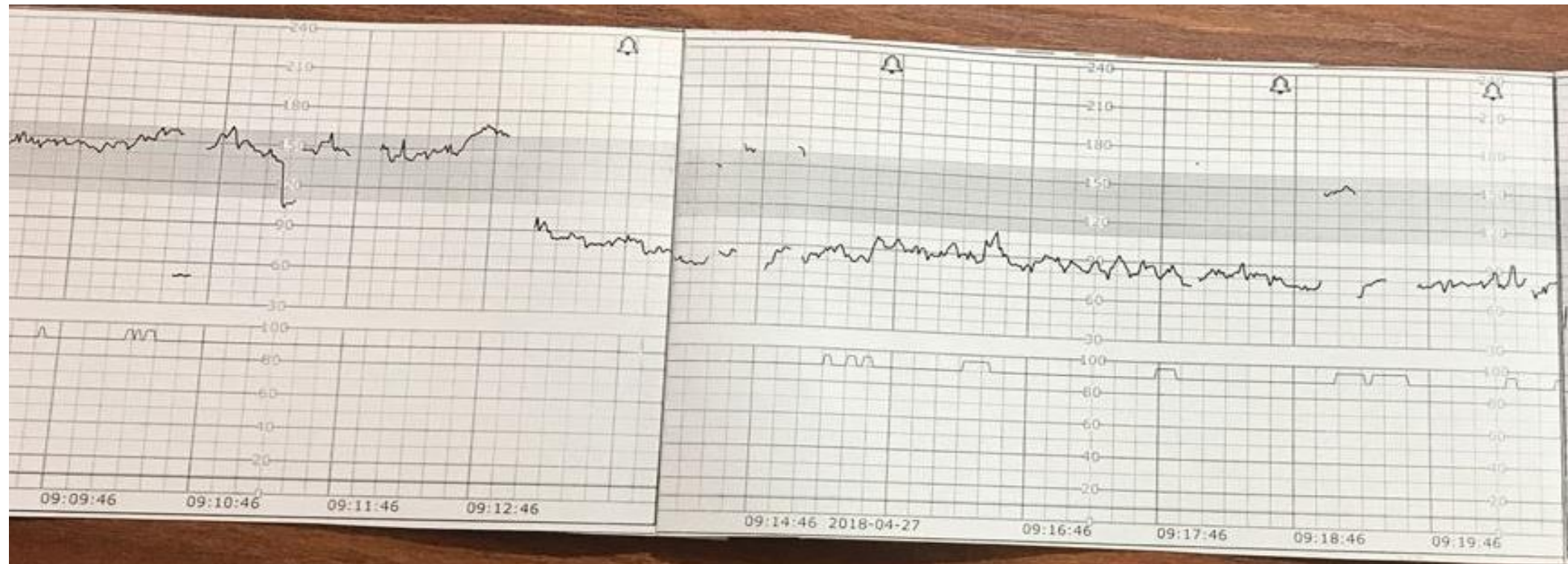4 AM: Vx / 3cm /60% /-3 / R/C Temp 37.3

6AM: Vx / 5cm /60% /-2/ R/C Temp 37.5 At

6:45 AM: sudden moderate to severe vaginal bleeding

Exam: Vx / 6cm /70% /-2 / R/bloody

V/S: PR: 110 RR:18 BP: 90/60 mmHg





The patient immediately was prepared & transferred to the OR

What are the risk factors of asphyxia?

What is the role of duration of labor in asphyxia?





- Does intrapartum FHR monitoring prevent asphyxia?
- Witch pattern of FHR has association with asphyxia?



After 20 minutes a baby boy was born with this condition:  
Flaccid, hypotonic & cyanotic with gasping & heart rate :50

What is the first step of CPR for this baby?

What are important points during CPR?



- was asphyxia happened?
- What are the diagnostic criteria of asphyxia?



## The baby's umbilical cord blood gas:

PH: 6.9

BE: -21

PCo<sub>2</sub>: 40

PO<sub>2</sub>: 30

O<sub>2</sub> Sat: 50%

- What is the role of fetal blood gas in diagnosis of fetal distress and asphyxia?
- What are the indications of fetal blood sampling ?



- Baby's condition after 20 minutes:

Heart rate: 110 Resp: shallow, intubate Pink Flaccid and hypotonic

The baby was transferred to NICU (he intubated and had convulsion)

What should be done for more protection of brain ?



- Are other systemic organs at risk of damage?
- Which laboratory data helps us in management of asphyxiated baby?
- What is the child's prognosis?
- What should be done in F/U of asphyxiated baby ?



اوینه ی دل من تنگ طلا بود تو شکوندیش  
بر چار دیوارش نقش وفا بود تو کروندیش  
دل افتاد و گفتی، آخ بیگیر نشکه بلوره  
نازک شده بود دل، به صدوی آخ تو شکوندیش  
آخر دل دیوونه که نم تک نمیداد پس  
اشکی شد و چکه چکه از چشم چکوندیش

زنده یاد بیژن سمندر